
CASE REPORT**An Atypical Presentation of Wegener's Granulomatosis in a Child***Rohit Bannerji¹, Avijit Mandal¹, Monjori Mitra¹, Jaydeb Ray^{1*}**¹Department of Pediatric Medicine, Institute of Child Health,
Kolkata-700017 (West Bengal) India***Abstract:**

Wegener's granulomatosis is an autoimmune small vessel necrotising vasculitis associated with both granulomatosis and polyangiitis. While its standard form involves the upper and lower respiratory tracts and kidneys, it may essentially involve any organ. We report a case of a 14 year old girl, admitted with fever, cough, haemoptysis, nose bleeds and following admission developed hoarseness of voice. There was anemia, elevated CRP. Chest X-ray and HRCT chest showed a cavitary consolidation of left upper lobe of the lung. In view of respiratory symptoms, fever, haemoptysis and radiological findings, the child was started on antitubercular therapy to which she did not respond. Subsequently she developed features of nephritis and Wegener's granulomatosis was suspected and confirmed by renal biopsy and positive c-ANCA. She was treated with steroids and cyclophosphamide to which she responded dramatically in our institution. We should suspect Wegener's granulomatosis in any child presenting with respiratory symptoms, nose bleeds and symptoms of nephritis. Presence of cough, haemoptysis, and fever with obvious consolidation with cavitations may not always be tuberculosis.

Keywords: Wegener's, Necrotising Vasculitis, Epistaxis, Pulmonary Tuberculosis

Introduction:

Wegener's Granulomatosis (WG), now known as Granulomatosis with Polyangiitis (GPA) [1, 2] is a very rare and potentially lethal necrotising vasculitis characterised by upper and lower respiratory tract involvement, glomerulonephritis and necrotising vasculitis of small and medium sized blood vessels. Initial presentation may be very atypical and elusive and it may easily be confused with tuberculosis in a tuberculosis endemic country like India, due to overlapping clinical features in both the diseases. We hope our case will add to the database of atypical presentations of WG and will aid clinicians particularly in developing countries so that the early diagnosis and treatment of this potentially fatal disease is not missed [3].

Case Report:

A 14 year old girl was admitted to our hospital with a history of fever, cough and weight loss for one month associated with recurrent episodes of haemoptysis and nasal bleeds since last 15 days. On examination she was found to be febrile, anaemic, haemodynamically stable with bilateral conjunctivitis and no other significant physical findings. Comprehensive laboratory investigations were done and revealed Haemoglobin of 8.4 gm/dl, CRP of 98 mg/L, normal leukocyte

counts, and urine showing plenty of pus cells with moderate RBCs and trace albumin. Mantoux test and GeneXpert in induced sputum were negative. All other routine haematological and biochemical parameters were within normal limits. Chest X-ray showed a homogenous opacity of left upper lobe of the lung and a High Resolution CT scan (Fig. 1) was done which confirmed a consolidation with cavitations in the left upper lung lobe [3]. Ophthalmologic opinion was taken and she was shown to have multiple phlyctens. Subsequently she developed hoarseness of voice and an E.N.T opinion was taken and a paranasal CT scan done in view of the nose bleeds which was normal. On the basis of long history of fever, cough, haemoptysis, presence of phlyctens and the HRCT findings she was suspected to have pulmonary tuberculosis and was started on antitubercular drugs. However there being no response to the anti tubercular therapy even after 10 days with worsening of symptoms and suspecting an alternate diagnosis, p-ANCA, c-ANCA, anti GBM antibodies, and anti dsDNA antibodies were also sent. All were found to be negative with the exception of c-ANCA which came out to be strongly positive. In the meantime the patient developed features of nephritis with gross haematuria and heavy proteinuria of 3+. In the background of respiratory symptoms, nephritis, nose bleeds and a strongly positive c-ANCA which is pathognomonic of Wegener's granulomatosis, a renal biopsy was done which confirmed the presence of segmental necrotising glomerular involvement with more than 50% crescents containing proliferating parietal epithelial cells along with neutrophils, pyknotic nuclear debris and macrophages.

The morphological and immunological findings were those of pauciimmune crescentic glomerulonephritis and in view of the epithelioid granuloma and ANCA positivity, the diagnosis of ANCA related glomerulonephritis: Granulomatosis with Polyangiitis (Wegener's granulomatosis) was firmly established. In view of significant renal and respiratory involvement the patient was started on oral prednisolone of 2mg/kg/day with intravenous cyclophosphamide (500mg/sq.m). Antitubercular drugs were stopped and oral co-trimoxazole was started for pneumocystis carinii prophylaxis along with other supportive care. Patient responded to the above treatment and is currently undergoing follow up treatment in our institution.

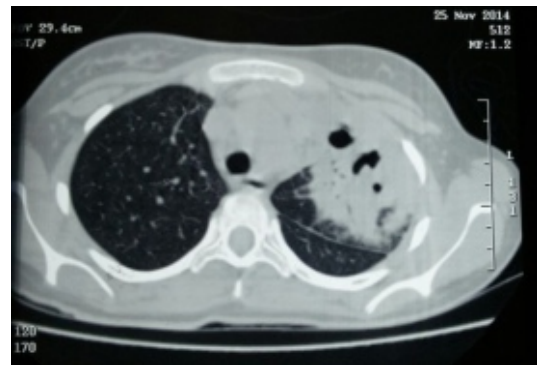


Fig. 1: HRCT showing Consolidation with Cavitations in Left Upper Lung Lobe

Discussion:

Wegener's Granulomatosis (WG) is a very rare systemic form of vasculitis involving medium and small sized blood vessels. It was first reported by Peter Mc Bride in 1897 [3] and subsequently described in details by Friedrich Wegener in 1936. It was renamed to Granulomatosis with Polyangiitis subsequently by professional bodies

and journals as Wegener was connected to the German Nazis [1, 2]. WG is an autoimmune necrotising vasculitis which is characterised by the classical triad of necrotising granulomatous inflammation of the respiratory tract (both upper and/or lower), necrotising focal or proliferative glomerulonephritis, along with widespread systemic autoimmune vasculitis of the small and medium sized blood vessels which can cause extensive damage to almost any organ system in the body. In India, two forms have been increasingly reported namely a limited WG (LWG) involving only upper and lower respiratory tract involvement; and the classical WG (CWG) with both respiratory and renal involvement [4]. WG is a part of a larger group of systemic necrotising vasculopathies which include Churg-Strauss syndrome and microscopic polyangiitis, all of which are believed to be caused by autoimmune attack of an abnormal circulating antibody which is known as Anti-Neutrophil Cytoplasmic Antibodies (ANCA) against medium and small sized blood vessels [5]. In particular, ANCA against Proteinase-3 (PR3-ANCA) detected in blood is highly specific for WG [6]. WG is an elusive disease and has non-specific features particularly in the initial stages and a strong index of suspicion is necessary for early diagnosis which is imperative for institution of early immunosuppressive therapy. In the absence of early immunosuppressive therapy, the disease spreads rapidly and is usually fatal. Classification and staging of this disease has been done by The American College of Rheumatology which has laid out the criteria for diagnosis in 1990 with four criteria namely nasal/oral inflammation, lung

involvement, glomerulonephritis, and granulomatous inflammation on biopsy [7]. All four criteria were met in our patient.

Clinical presentations include primarily upper respiratory (sinusitis, nasal ulcerations, epistaxis), lower respiratory (haemoptysis, cough, dyspnoea) and renal symptoms (haematuria, proteinuria, hypertension), all of which was present in our patient except that she was always normotensive. Necrotizing vasculitis is the cardinal histologic feature in WG. Kidney biopsies typically demonstrate crescentic glomerulonephritis with little or no immune complex deposition (“pauci-immune”) as was characteristically seen in our patient.

WG is a very elusive disease and as seen in our case it presented with a clinical, ophthalmic (phlyctens) and radiological picture of classical pulmonary tuberculosis. Similar atypical presentations have been reported on rare occasions in the past from tuberculosis endemic developing countries like India [8] and Bangladesh [9]. It is vital not to miss the diagnosis early because early initiation of immunosuppressive therapy with steroids and cyclophosphamide can lead to overall 5 year-survival rates in excess of 80% [10].

Thus a high index of suspicion for WG should always be there whenever a patient presents with upper and lower respiratory tract symptoms, epistaxis, renal manifestations because early diagnosis and treatment can lead to improved outcomes in majority of patients [10].

Fever, haemoptysis, cough, cavitations with consolidation on CT and X-Ray may be easily

confused with pulmonary tuberculosis particularly in tuberculosis prevalent countries like India and the above, with or even without renal involvement should always prompt for a search for WG.

Wegener's Granulomatosis is a rare and invariably fatal form of systemic vasculitis, but early diagnosis and management have significant positive impact on future outcome and prognosis. We believe that our case will emphasize the need, particularly in a Tuberculosis endemic country like India to always look for systemic vasculitides like WG in all patients presenting initially as pulmonary tuberculosis because the renal manifestations of WG may not be evident in the

initial phases of the disease and maybe easily overlooked thus leading to an unnecessary delay in the diagnosis which may cost the patient his/her life.

Conclusion:

Wegener's Granulomatosis is a rare and invariably fatal form of systemic vasculitis, but early diagnosis and management have significant positive impact on future outcome and prognosis. Study of this case emphasizes the need for careful consideration and systematic analysis of patient's presenting respiratory symptoms and signs suggestive of pulmonary TB, and hence that the diagnosis of systemic vasculitis like WG will not be missed or delayed.

References

1. Falk RJ, Gross WL, Guillevin L, et al. Granulomatosis with Polyangiitis (Wegener's): an alternative name for Wegener's granulomatosis. *Ann Rheum Dis* 2011; 70(4):704
2. Jennette JC. Overview of the 2012 revised International Chapel Hill consensus Conference nomenclature of vasculitides. *Clin Exp Nephrol* 2013; 17(5):603-6
3. Friedmann I. McBride and the midfacial granuloma syndrome(The second 'McBride lecture', Edinburgh, 1980. *JLaryngol Otol* 1982; 96(1):1-23
4. Pradhan VD, Badakere SS, Ghosh K, et al. ANCA: serology in Wegener's granulomatosis. *Indian J Med Sci* 2005; 59(7):292-300
5. Seo P, Stone JH. The antineutrophil cytoplasmic antibody-associated vasculitides. *Am J Med* 2004; 117(1):39-50.
6. Van Der Geld YM, Limburg PC, Kallenburg CG. Proteinase 3, Wegener's autoantigen: from gene to antigen. *JLeukoc Biol* 2001; 69(2):177-90.
7. Leavitt RY, Fauci AS, Bloch DA et al. The American College of Rheumatology 1990 criteria for the classification of Wegener's granulomatosis. *Arthritis Rheum* 1990; 33(8):1101-7.
8. Pandhi N, Kajal NC, Nagaraja CL et al. Wegener's granulomatosis disease mimicking pulmonary tuberculosis. *J Assoc Chest Physicians* 2015; 3:63-5
9. Alam A, Dastider R, Ahmed Z, et al. Wegener's granulomatosis mimicking pulmonary tuberculosis. *J Bangladesh Coll Phys Surg* 2012; 30:98-104
10. Berden A, Göçeroglu A, Jayne D, et al. Diagnosis and management of ANCA associated vasculitis. *BMJ* 2012;344:e26

Author for Correspondence: Dr Jaydeb Ray, Department of Pediatric, Institute of Child Health, Kolkata-700017, West Bengal, India Email:jaydeb_ray@hotmail.com Cell: 09831054552